

Expert Consensus on Achieving Optimal Outcomes With Absorbable Suspension Suture Technology for Tissue Repositioning and Facial Recontouring

Z. Paul Lorenc MD FACS,^a Glynis Ablon MD,^b Julius Few MD,^c Michael H. Gold MD,^d David J. Goldberg MD JD,^e Stephen Mandy MD,^f Mark S. Nestor MD PhD,^g and Susan H. Weinkle MD^h

^aLorenc Aesthetic Plastic Surgery Center, New York, NY;
Lenox Hill Hospital, New York, NY

^bUniversity of California, Los Angeles, CA;

Ablon Skin Institute Research Center, Manhattan Beach, CA

^cFew Institute for Aesthetic Plastic Surgery, Chicago, IL;

University of Chicago Pritzker School of Medicine, Chicago, IL;
Northwestern University, Evanston, IL

^dGold Skin Care Center, Nashville; Tennessee Clinical Research Center, Nashville, TN;
Vanderbilt University School of Nursing, Nashville, TN;

Meharry Medical College, School of Medicine, Nashville, TN

^eSkin Laser & Surgery Specialists of NY/NJ;

Icahn School of Medicine at Mount Sinai, New York, NY;
Fordham Law School, New York, NY

^fSouth Beach Dermatology, Miami Beach, FL;

University of Miami Miller School of Medicine, Miami Beach, FL

^gCenter for Clinical and Cosmetic Research, Center for Clinical Enhancement, Aventura, FL;

University of Miami Miller School of Medicine, Miami, FL

^hBay Area Medical Complex, West, Bradenton, FL

ABSTRACT

A complete approach to facial rejuvenation includes restoration of the skin's surface, relaxation of muscles that contribute to hyperkinetic movement, revolumization, and repositioning/recontouring of descended tissues and fat pads. After receiving 510(k) clearance from the US Food and Drug Administration (FDA) in 2015, the Silhouette InstaLift™ absorbable suspension suture became the only available non-surgical technique for repositioning of facial tissue. In January 2017, a consensus paper presented a review of the literature on the efficacy and safety of absorbable suspension sutures and provided information on treatment procedures. Since that time, the clinical experience of the authors has further shaped their treatment practices, highlighting the need for additional guidelines to support an optimal treatment approach. This update will expand upon the 2017 consensus paper on the safety and efficacy of absorbable suspension sutures and provide guidance for obtaining consistently high patient satisfaction with the procedure. Recommendations are based on the extensive clinical experience of expert physicians with absorbable suspension sutures over the past 2.5 years. Here, the authors provide guidance on full face assessment and treatment to support maximum benefit and provide patient selection and procedural recommendations. In addition, the authors stress the benefits of the dual mechanisms of action within the absorbable suspension suture: the immediate lift and volumizing over time that together lead to the outcome of recontouring.

J Drugs Dermatol. 2018;17(6):647-655.

INTRODUCTION

The hallmarks of facial aging include diminished skin tone, increasingly uneven texture, appearance of wrinkles, volume loss, and the descent of facial features.¹ Age-associated decreases in ligament stability and involution of bony attachments, coupled with the descent of the fat compartments and changes in musculature, cause the inferior displacement of tissue characteristic of facial aging.²⁻⁴ Compounding this loss of underlying support is an increase in skin laxity

caused by a reduction in the supportive capacity of collagen and dwindling levels of elastin.⁴ Together, these physiological changes result in increased prominence of the nasolabial fold, redistribution of tissue along the jowl, and descent of facial features (inferior displacement).

A complete approach to facial rejuvenation and restoration generally requires that multiple aspects of facial aging be

© 2018-Journal of Drugs in Dermatology. All Rights Reserved.

This document contains proprietary information, images and marks of Journal of Drugs in Dermatology (JDD).

No reproduction or use of any portion of the contents of these materials may be made without the express written consent of JDD.

If you feel you have obtained this copy illegally, please contact JDD immediately at support@jddonline.com

addressed. Treatment plans may include resurfacing with lasers, skin tightening with energy-based treatments, relaxation with neuromodulators, revolumization with fillers, and repositioning of descended tissue.⁵ In a global composite approach, correction of inferior displacement through repositioning ensures an optimal outcome for each of the other modalities used. Prior to the 2015 FDA 510(k) approval of the Silhouette InstaLift™ absorbable suspension suture (Sinclair Pharma, London, UK) for use in the midface,⁶ the primary tool to address inferior descent was surgical facelift or placement of a permanent suture that required open dissection of the temporal fascia with suture fixation to the fascia. While fillers represent a non-invasive method that can reverse the descent of facial features to some degree through their capacity to restore volume and support overlying tissues, they are not designed to reposition tissue, and their theoretical capacity for lifting is limited by the need for natural looking and aesthetically balanced results. The Silhouette InstaLift™ absorbable suspension suture is not only the single available non-surgical tool for repositioning, but also serves to recontour and revolumize through the activities of the PLLA and PLGA within the suture/cones. Furthermore, absorbable suspension suture technology is a modality supportive of complementary treatments such as energy-based devices, fillers, and toxin, and is an important element of the holistic approach to rejuvenation that yields high patient satisfaction.

The Silhouette InstaLift™ Suture

The Silhouette InstaLift™ absorbable suspension suture is unique in that the cones are oriented in a bidirectional fashion along the suture (Figure 1) and that the device is entirely absorbable. Both the suture and the cones are composed of 18% poly lactic-co-glycolic acid (PLGA) and 82% poly-L lactic acid (PLLA). Use of absorbable suspension suture technology affords a non-surgical, segmental approach for the treatment of facial laxity that can correct inferior displacement by targeted repositioning of descended tissue. Recovery time following suture placement is minimal, and results are evident immediately.

While the physical lifting capacity of the suture itself is diminished as the suture is absorbed, the complementary collagen-stimulating

properties of PLLA/PLGA^{7,8} within the suture provides revolumization that permits a sustained recontouring of the treated area for 18 to 24 months following placement.^{9,10} In addition, adhesion or “holding” of tissue in the uplifted position occurs as a result of the suture passing through an immediately subdermal glide plane, where the cones lift descended tissue at the retaining ligament level and then adhere the tissue in place as a result of neocollagenesis. Recontouring, rather than mechanical lift alone, is the basis of the ongoing improvement in patient appearance at 12 months and beyond, and this improvement is reflected by high patient satisfaction at 12 to 18 months.^{9,10} For example, patient responses to the FACE-Q questionnaire indicated an ongoing improvement at 12 months in cheek contour and attractiveness, among other measures. For the patient shown in Figure 2, effacement of the nasolabial fold and marionette line is apparent at 6 months, and the jowl visibility is reduced and there has been a significant enhancement of jawline definition that is maintained until 18 months. Twelve months post procedure, the improvement to the nasolabial fold and marionette line is sustained, and revolumization in the midface has improved the contour of the cheek. At 24 months, a degree of replenished volume is retained in the midface. This timeline is reflected in the overall experience of the authors: patients often do not require retreatment for 18 to 24 months. In addition to the immediate lift provided, the physiochemical properties of the suture material address age-related volume loss, offering another mode by which repositioning with this product can yield optimal results. The impact of sutures on midface volume are apparent in Figure 3, where at 15 months, recontouring in the cheeks can be observed in the frontal and profile views, where both the position and projection of the cheek is improved, and midface volume is replenished. As the degree of revolumization is linked to the amount of PLLA placed in the cheeks, the use of at least 3 sutures in the midface supports desired repositioning and recontouring.

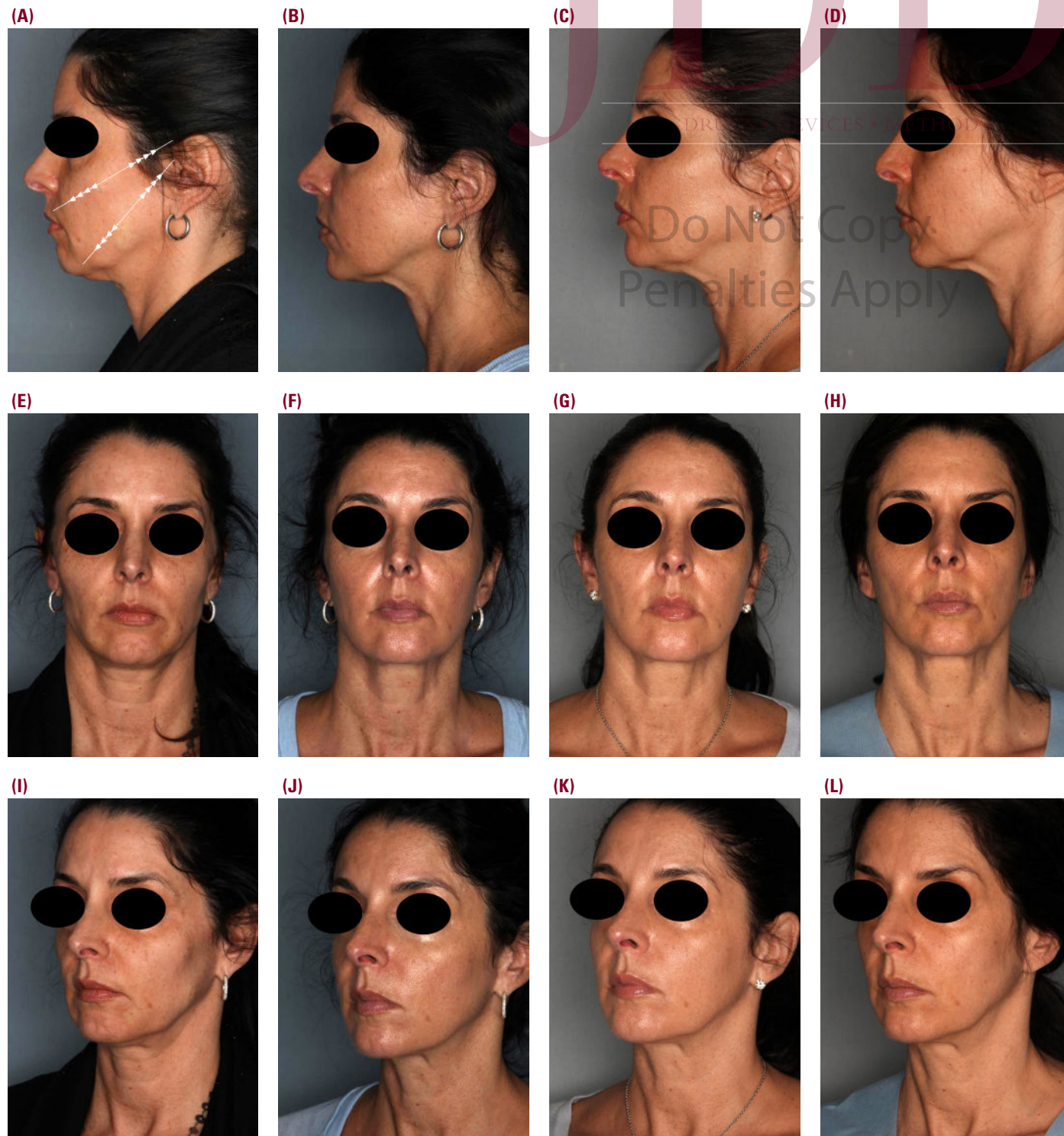In July 2017, the authors of this manuscript published a consensus paper on the safety and efficacy of absorbable suspension sutures. Since the time when the first consensus manuscript was originally submitted (January 2017), the collective clinical experience of the authors with this technology has continued to grow, and ongoing communication within the group led to

FIGURE 1. The InstaLift™ absorbable suspension suture. The suture is comprised of 8 bidirectional cones to support elevated tissue in a fixed position.



FIGURE 2. Strategically placed sutures in the midface and jawline result in lift and recontouring. A 47-year-old female treated with four 8-cone sutures, 2 on each side of the face placed strategically along the jawline and in the midface (**Panel A**). Follow-up profile view at 6 months (**B**), 18 months (**C**), and 24 months (**D**) following treatment. Pre-procedure frontal view (**E**) and follow-up at 6 months (**F**), 18 months (**G**), and 24 months (**H**) following treatment. Pre-procedure oblique view (**I**) with follow-up at 6 months (**J**), 18 months (**K**), and 24 months (**L**) following treatment. The patient remained on her 4-month cycle of treatment with neuromodulators (standard, FDA-indicated dosing) in the glabella and crows' feet throughout the course of treatment.

Provided courtesy of Julius W. Few, MD, FACS.



© 2018-Journal of Drugs in Dermatology. All Rights Reserved.

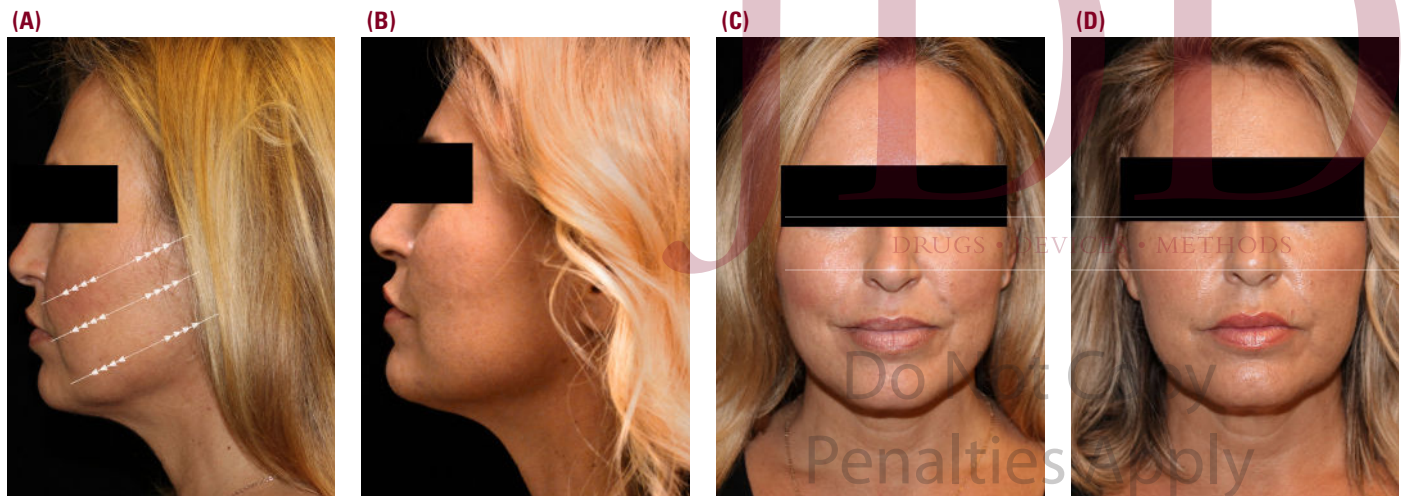
This document contains proprietary information, images and marks of Journal of Drugs in Dermatology (JDD).

No reproduction or use of any portion of the contents of these materials may be made without the express written consent of JDD.

If you feel you have obtained this copy illegally, please contact JDD immediately at support@jddonline.com

FIGURE 3. Impact of sutures in the midface on tissue position and facial contour. 49-year-old female patient treated with three 8-cone sutures. Baseline profile view (A) and results at 15 months (B) are shown. Baseline frontal view (C) and results at 15 months (D). The patient was retreated with a single suture at 16 months.

Provided courtesy of Michael H. Gold MD.



recognition of a need for an additional publication detailing the lessons learned over the past 12 to 18 months. With the approval of a new technology comes a need to optimize patient selection, clarify the details of an ideal treatment approach, determine how to best use the new technology in combination with other modalities, and offer guidance on how to best prevent and manage any adverse events. Within this update, the authors provide a consensus on each of the above elements of patient care, with special consideration for maximizing the high patient satisfaction achievable with absorbable suspension sutures.

Patient Selection

Absorbable suspension sutures provide a minimally invasive option for highly specific, segmental treatment of facial laxity. Candidates for absorbable suspension sutures often desire facial recontouring but require repositioning of facial tissue beyond what fillers can provide through volumization alone. These patients may not yet be a candidate for a surgical facelift; may wish to delay the procedure for personal or financial reasons; are unwilling to undergo surgery or require minimal down time; or have already had a facelift and wish to extend the results. In each scenario, the patient should be appropriately counseled about the expected results. The lift provided by absorbable suspension sutures is not a substitute for a surgical facelift. Rather, the sutures provide a combination of repositioning and volumization that give rise to a recontouring that is unique to this device. Further, absorbable suspension sutures can be used with a wide range of complementary treatments to achieve optimal results.

Absorbable suspension sutures are a highly adaptable treatment that may benefit a wide array of patients. Below, the characteristics of the “ideal” patient are presented; however,

there are many patients outside of this ideal for whom suspension sutures are an appropriate and beneficial treatment. In each of these categories, clear communication between patient and physician is key for shaping patient expectations.

The “Ideal Patient”

The “ideal” patient has strong bony projections, skin of sufficient thickness to prevent palpability of the suture, as well as pliability and mobility to allow for repositioning. The patient may have a visible nasolabial fold, visible marionette lines, loss of definition along the mandibular boarder, and/or jowling, as well as some redundancy of the skin. Patients often have an additional need for volume restoration due to excess ptosis of skin that cannot be managed by filler placement only. Patients with thin skin, excessive fibrosis, sun damage, or excessive local rhytids are generally not the best candidates for absorbable suspension sutures alone.

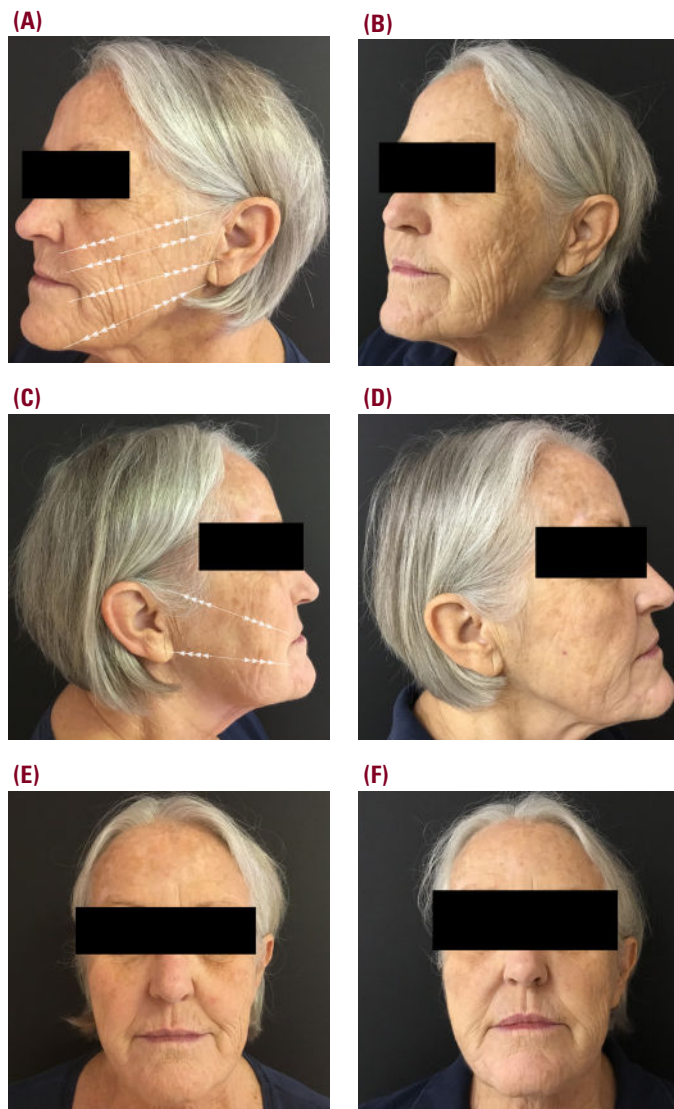Mature Patients

Mature patients also benefit from tissue repositioning and recontouring. While loss of elastic tissue fibers and a diminished ability to produce collagen may reduce the degree of volumization achieved by the suture’s PLLA/PGLA, tissue may still be effectively repositioned in mature patients and some benefit from the biostimulatory activities of PLLA/PGLA likely obtained. Absorbable suspension sutures are an important treatment modality for patients who are not candidates for a surgical facelift or who wish to maintain the results of a previous procedure without further surgical intervention. Of note, the difficulty in concealing scars from a surgical facelift in men makes absorbable suspension sutures a particularly useful treatment option for male patients.

Sun-damaged skin may be encountered more frequently in this population. In these patients, the increased capillary fragility and comparatively thinner dermis may lead to more bruising; however, the patient may be counseled on the relative risk. For the patient shown in Figure 4, absorbable suspension sutures were able to address both facial asymmetry and inferior displacement. For patients who are not a candidate for surgery, the effacement of the nasolabial fold, tissue repositioning

FIGURE 4. Meaningful results from sutures in mature patients and correction of asymmetry. A 70-year old female treated with four 8-cone sutures on her left side at baseline (A), and 9 weeks after treatment (B) and two 8-cone sutures on her right side at baseline (C) and 9 weeks after treatment (D). The baseline frontal view (E) and frontal view at 9 weeks post treatment (F) are shown. Treatment addressed facial asymmetry, volume loss, and the need for tissue repositioning. Variation in the number of sutures on each side of the face speaks to the flexibility of the procedure for achieving patient aesthetic goals.

Provided courtesy of Susan H. Weinkle MD.



throughout the cheek and midface, and the improved definition of the jaw line achievable with absorbable suspension sutures is often a procedure with high patient satisfaction.

Additional Patient Populations

Initial recommendations in the first consensus paper underestimated the potential of absorbable suspension sutures in thicker-skinned patients, as the authors have subsequently found that positive outcomes are achievable if a sufficient number of sutures is utilized and the skin is of sufficient mobility and pliability.

DRUGS • DEVICES • METHODS

Absorbable suspension sutures are a valuable tool for the treatment of patients with round faces who require volume correction or reshaping, but for whom fillers are not ideal, or for the management of facial asymmetry.

Patients with very early signs of inferior displacement of facial features are also excellent candidates for absorbable suspension sutures. Candidates for prejuvenation may be genetically predisposed to early development of a more pronounced nasolabial fold or jowling. In these patients, placement of comparatively fewer sutures on each side is a procedure associated with high patient satisfaction. Ideal candidates for prejuvenation wish to prevent or minimize the progression of tissue inferior displacement, are comfortable with injections and aesthetic medicine, and have sufficiently mobile skin.

Pre-Treatment Planning

Placement of absorbable suspension sutures takes approximately 30 minutes in the hands of a skilled practitioner. The most time-intensive phase of suture placement is pre-treatment planning; the procedure itself is technically straightforward and highly adaptable. The number of sutures may be easily increased to suit the needs of the individual patient, as using the marked entry and exit points of other sutures as a guide eliminates the need to re-measure the patient should the need for additional sutures emerge after the procedure has begun. The number of sutures should be adjusted to suit individual patient treatment goals and may be different on each side of the face to account for asymmetry. While treatment must be adapted to suit the needs of individual patients, there are several considerations that have emerged as critically important over the past year that the authors wish to emphasize.

First, physicians interested in adding absorbable suspension sutures to their practice should seek out training by contacting a Silhouette InstaLift™ representative or by submitting a request through www.instalift.com. In addition, there are CME resources available that include videos of the procedure performed by authors of this publication available through X-Medica, LLC. The procedure is technically straightforward, and the learning curve is easily managed; however, proper technique is critically

important for optimal outcomes. Second, the 8-cone suture is preferred for all applications in the face. Third, for many patients in need of facial tissue repositioning in multiple distinct anatomical areas, a minimum of 4 sutures per side provides the needed mechanical benefit to achieve and maintain a meaningful degree of repositioning. While the technique should be tailored to suit the needs of individual patients, the authors generally recommend 3 to 4 sutures per side in the midface for moderate to severe mid-facial aging and 2 to 3 sutures in the midface for mild to moderate mid-facial aging (Figure 2).¹¹ Common arrangements include 2 to 4 sutures in the midface with additional sutures placed as needed to address other areas such as jowling or jawline definition. A sufficient number of sutures ensures that the lifting capacity of the sutures is not surpassed by the amount of advanced tissue and that the mechanical burden on each individual suture is minimized, that the tissue to be repositioned (the zone of action) is evenly distributed over the sutures, and that the collagen stimulated by the PLLA/PLGA that comprises the sutures is sufficient to replenish volume and support both recontouring and ongoing tissue repositioning as the suture is absorbed. Undercorrection, either through placing a suboptimal number of sutures or failing to correctly advance the descended tissue, is not only detrimental to patient satisfaction but is a lost opportunity for use of an otherwise effective treatment.

Though sutures should be placed to best support treatment goals, several canonical pathways of midface sutures are shown in Figures 2, 3, and 4. While early research on absorbable suspension sutures focused upon outcomes for on-label indications such as cheeks and nasolabial folds, the jowls and jawline definition should be considered part of a complete treatment plan.¹² The contour of the jawline and the position and contour of the jowls strongly influence the impact of treatment in other parts of the midface and neck, and so should be included in patient evaluation.

Straight Line Vector Planning

For all applications, the issue of straight-line vector planning (SLVP) has evolved as a central principle for ensuring both efficient and enduring tissue repositioning. In order for the suture's opposing cones to act in concert to provide support and lift, they must be oriented in a straight line (Z.P. Lorenc, MD, personal communication). Placement of the suture in a "U" or "V" formation diminishes the additive ability of the cones on each side of the suture to reposition tissue and dilutes the opposing forces of the bidirectional cones, increasing the likelihood of suture displacement and reducing the overall lifting capacity of the suture. In addition, placement of the suture so that it is perpendicular to the plane it is intended to elevate ensures that all of the supportive force exerted by the suture is directed towards repositioning the tissue it is intended to elevate, rather than diluted by an improper angle. For example, a suture

intended to elevate the nasolabial fold should be placed perpendicular to the descended feature (Figure 2). Together, these principles of SLVP ensure that the lifting capacity of the sutures and clinical result are maximized.

Once the aesthetic needs of the patient have been determined, the tissue that is to be repositioned, referred to here as the zone of action, is identified. The entry and exit points of the suture should be determined and marked with the patient in a full upright position so that the areas to be addressed are evaluated in their most natural state. During the procedure, the patient is reclined at a 45° angle for suture placement. In general, the exit point should be placed 1.5 cm past the point of action to allow for tissue movement (so that the inferior-most cone resides at the point of action). For the nasolabial fold, the inferior-most exit point is tangent to the lateral side of the of the nasolabial fold. For each suture, 1 entry site and 2 exit sites are marked, beginning with the points of action and distal exit site, then both the central entry point and proximal exit point are measured and marked along the planned straight-line vector.

Suture Placement

Once the entry points and exit points have been marked, 1% lidocaine with epinephrine (1:100,000 dilution) is injected at the entry and exit sites. No lidocaine should be injected into the suture paths, as this may cause swelling and interfere with patient ability to sense pain, an important indicator that the needle is in the incorrect plane. To minimize patient discomfort, use a 32 gauge needle to administer 0.5 cc at each entry and exit site. To sufficiently dilate the entry point opening (exit points to not require an opening to be made in advance), insert an 18 gauge needle into the subcutaneous tissue perpendicular to the skin to a depth of 5 mm. Prior to inserting the suture, the suture should be grasped near the last cone on each side and pulled taut to tension, thus tightening the knots. Applying excessive tension to the suture by grasping the 2 needles can overstress the connection between the suture and needle, leading to breakage.

Sutures are then placed using the 23 gauge, 12 cm needle appended to each suture. First, the needle should be inserted at the entry point in a perpendicular fashion, using the 5 mm depth gauge on the needle as a guide. Once the needle is at a 5 mm depth, the needle is turned at a 90° angle into the subcutaneous plane. The natural tendency is to withdraw the needle slightly prior to turning it; however, it is important to maintain the 5 mm depth so that the sutures are not placed too superficially. Once the needle is turned, it is carefully advanced toward the exit point, maintaining depth in the subcutaneous plane until the exit point is reached. The needle should pass easily through the subcutaneous layer without resistance: patient discomfort is an indicator that the needle is either too shallow or too deep and no longer in the correct plane. Should the patient show any signs of discomfort during placement, gently back the needle

up until it is in the correct plane. A needle cap may be used to catch the needle as it passes through the exit point. Once the tract has been created, the suture must be pulled through from the entry point. Slight counter traction on the opposite side of the entry point from the direction of needle travel permits the cones to easily pass through the entry point. When pulling the suture into position, it is important that the tension applied to the suture be directly in line with the needle tract. Otherwise, the tension can act as a lever and cause the cones to “catch” on the dermis. Insert the needle appended to the other side of the suture through the same entry point, following the direction of the initial needle tract until the 5 mm depth mark is reached. It is important to place the needle in the same entry point in order to avoid a dermal bridge at the entry site where the suture is too superficial. Either side of the suture may be placed first, depending on the preference of the physician.

Once the suture is in place, tension the suture on both sides to ensure there is no depression at the entry site. When the suture is tensioned, the skin will remain evenly taut, and there should not be dimples at any point along the length of the suture, as dimples are an indication that the depth of the suture is varied, and cones are caught on the dermis. Dimples at the entry point indicate a small skin bridge resulting from needle entry at slightly different points. Any observed dimples at the entry point may be dissipated by gentle massage directly over the affected area or subcision using the 23 gauge needle if necessary. After proper placement is confirmed, apply tension to the inferior portion of the suture, and grasping the suture itself rather than the needle, begin the tissue elevation process by advancing the tissue in the zone of action over the lower cones, engaging the cones. Then, apply sufficient tension to the superior aspect of the suture to further and fully elevate the tissues in the zone of action to the desired position, and while holding tension to maintain this desired level of correction and tissue movement, massage the tissue over the superior cones to seat them into place to anchor the superior aspect of the suture. Anchoring the suture will maintain this desired level of elevation. Slight and transient pleating or puckering may be observed but can be expected to resolve within 2 to 3 days. As during placement, the force applied to the suture must be along a single, straight vector in line with the needle track. Incorrectly applied tension can disengage the cones. Seat the suture by massaging the dermis overlying the superior cones in the direction of the exit point. Allow sutures to rest for a few minutes, and then adjust further if needed. At this point, if any further adjustment is needed within the zone of action, the tissue may be moved over the cones. Any visible gathering or slight pleating of the skin can be expected to dissipate within 2 to 3 days.

The degree of necessary correction varies from patient to patient and is largely dictated by pre-treatment plan. While the amount of tissue advancement or suspension required to

achieve adequate repositioning may seem to be an overcorrection, this level of tissue elevation is central to obtaining optimal results and is a valid aspect of treatment.

If at any time during the procedure a cone becomes exposed due to disengagement or during tissue advancement, the cone may be trimmed from the suture so that the suture end remains beneath the surface of the skin. Suture breakage is uncommon, but if it does occur, the suture need not be removed, as the material is entirely absorbable. While proper treatment planning and technique obviates the need to manage any asymmetry following the procedure, additional sutures may be added to ensure an optimal result. The results should be evaluated with the patient upright prior to trimming the suture ends. If a need for adjustment to the degree of tissue advancement emerges once a patient is upright, they may be reclined once again to adjust tissue advancement over the appropriate suture.

Post-Procedure Care

Though placement of absorbable suspension sutures is a minimally invasive procedure, it does require diligent adherence to post-care instructions. Post-procedure recommendations presented here are somewhat less restrictive than in the authors' 2017 consensus paper but must be followed to ensure optimal outcomes.

Once the procedure is completed in the office, ice is applied for 30 minutes and Aquaphor® is applied to puncture sites. While patients may be instructed to continue icing for 24 hours, it should be noted that patients often apply too much pressure when icing at home and should either be instructed not to do so or instructions to ice at home may be omitted all together. Patients may wash their face or apply makeup after 24 hours, but these activities must be gentle, and pushing or pulling of the skin should be avoided. Early animal studies show that tissue integration of the suture's knots is complete at one week, and the pull-out force of the suture plateaus at this time (Z.P. Lorenc, MD, personal communication). Therefore, great care should be taken not to disturb the suture with physical forces resulting from rigorous application of makeup, cleansing, chewing (a relatively soft diet is recommended), and distorting facial expressions such as grimacing for 1 week. During this week, patients should keep their head elevated on 2 pillows at night. Additional common activities that should be avoided include face-down massages, dental procedures or cleanings, and high impact exercise. Follow-up should include an office visit 3 to 5 days after treatment and again at 2 weeks if necessary.

Nature and Duration of Outcomes

Though the physical lifting capacity of absorbable suspension sutures is responsible for immediate results and initial repositioning, the initial lift is complemented by a longer-lasting recontouring effect that is reflected by both patient- and investigator-reported

measures of improvement and patient satisfaction. These positive changes have been shown within the context of a clinical study to endure for at least 12 months, but in the experience of the authors benefit endures for between 18 and 24 months.^{9,10} Because collagen stimulation by the PLLA/PLGA within the suture is not complete for between 4 and 6 months,¹³ it stands to reason that the mechanical and biostimulatory qualities of the suture act in concert to reposition and recontour facial tissue as well as improve skin quality. While “lift” in its purely technical sense may be considered the primary outcome of absorbable suspension suture treatment, the qualitative improvements in skin texture and contour are equally as important. This longer-term improvement is reflected by the authors’ experience with retreatment. In most cases, patients do not require retreatment for 24 months: generally, the revolumization that occurs as a result of PLLA/PLGA-induced collagenases obviates the need for additional suture placement before that time. In some cases, retreatment may include fewer sutures than the initial treatment. For example, the patient in Figure 3 was retreated at 16 months with a single suture.

Preventing and Treating Adverse Events

As with any medical procedure, a detailed knowledge of potential adverse events and how to best treat them is critical. Within the last 12 months, the adverse event rate per 106,810 devices sold is 0.006%.¹⁴ This remarkably low rate mirrors that observed for Silhouette Soft™ (Sinclair Pharma, London, UK), a physiochemically equivalent suture of similar design available in Europe.¹⁴ Swelling is relatively common, primarily as a result of the lidocaine injections, and dissipates within 2 to 3 days. Bruising is rare and may be managed by icing the area or treatment with lasers. While some practitioners may argue that patients should not take blood thinners for 1 week prior to suture placement, the potential risk of stopping blood-thinning therapy outweighs the increased likelihood of bruising. The patient should be counseled to avoid medically unnecessary supplements that may increase bruising, including vitamin E, garlic, ginger, and ginkgo. While hypersensitivity is rare, it does occur, and several case studies suggest that it can be successfully managed with steroids (Z.P. Lorenc, MD and M.S. Nestor, MD, PhD, personal communication). While minor bleeding consistent with a puncture is part of the treatment process, post-procedure bleeding or profuse bleeding during the procedure are rare and should be treated immediately. The patient should not experience pain during the procedure, and discomfort is a sign that the needle is outside of the correct plane.

Recommendations for Combination Treatments

While initial recommendations focused on treatment with absorbable suspension sutures as a single modality,⁵ the Silhouette InstaLift™ device is supportive of combination treatment with energy-based devices, neurotoxin, or fillers. These additional treatments not only enhance the impact of the procedure

but are an important aspect of a complete treatment approach. Energy-based devices should ideally be used 6 weeks prior to suture placement so that the treatment does not disrupt the suture once it is placed. Neurotoxin is generally administered 1 week prior to suture placement and can be used to relax hyperkinetic muscles, alleviating the degree of force exerted on the cones, thereby maximizing their tissue repositioning potential. Volume replacement with fillers may be completed either 6 weeks prior to suture placement to permit integration and dissipation of swelling or administered on the day of the procedure. Generally, areas in which the suspension suture has been placed should not be treated with additional modalities on the day of the procedure, and only adjacent or distinct anatomical areas may be managed with filler or toxin. In some cases, however, lifting tissue can unmask volume deficits, and patients with moderate to severe volume deficits may be given fillers in those areas as long as fillers are placed outside of the subcutaneous plane. If administering fillers to an anatomical area where sutures have been placed, it is important to account for the eventual volume that results from the PLLA/PLGA within the sutures.

Emerging Developments

The applications of absorbable suspension sutures continue to expand, and research continues to emerge on more systematic inclusion of the jawline and jowls in initial patient assessments, as well as optimal application of absorbable suspension suture technology to the neck. Indeed, for some experienced practitioners, a practical approach to treatment may include 2 to 4 sutures in the midface, 1 to 2 sutures in the jowls or along the jawline, and 2 in the neck. Overall, the number of sutures needed for a holistic treatment approach that includes the midface, jowls, jawline, and neck is between 6 and 8 sutures per side. Utilization of this higher number of sutures reflects the interplay between each of these distinct segmental treatment areas. For example, the improvements gained by repositioning in the midface and jowls is further highlighted by improving jawline definition. While there have been some reports of sutures used for brow lifts, the results of the procedure are ambiguous, and patient satisfaction may be limited.

CONCLUSION

Absorbable suspension sutures fill an important gap in the treatment armamentarium: they provide a minimally invasive option for tissue repositioning that is expanding to include several distinct anatomical areas within the face and neck. Utilizing absorbable suspension sutures as a recontouring treatment in these areas, rather than as a basic lifting technique or surrogate for a surgical facelift, is critical for meeting patient expectations and ensuring high patient satisfaction. The recommendations presented here, including proper patient selection, vector determination, and suture placement can serve as a guide for physicians who hope to further develop their expertise and

utilize absorbable suspension sutures more frequently in their practice as part of an evolving tool set to maximize clinical results and patient satisfaction.

DISCLOSURES

Dr. Lorenc is a consultant for Johnson & Johnson, Merz, Allergan, Galderma, Sinclair Pharma, CorMedix, ThermiAesthetics, and Almirall Pharma. Dr. Ablon is an Associate Clinical Professor at UCLA, consultant and advisory board member for Galderma, Sinclair, Thermi-Almirall, Erchonia, Sunetics, Nutrafol, and Lifes2Good. Dr. Few is a consultant and investigator for Sinclair Pharma and a consultant and investigator for Allergan, Galderma, Merz, Venus Concepts, and Zeltiq. Dr. Gold is a consultant for Sinclair Pharma and Thermi-Almirall. Dr. Goldberg is a consultant for Sinclair Pharma. Dr. Mandy is a consultant for and has received salary from Almirall and Sinclair Pharma; is an advisory board member for and has received honoraria from Galderma USA and Valeant Pharmaceuticals; is an advisory board member for Merz Aesthetics; and has received honoraria from Procter & Gamble Company and from International Speaker & Faculty Education. Dr. Nestor is a consultant and advisory board member for and has received research grants from Sinclair Pharma, and is a consultant, advisory board member, and speaker for Thermi-Almirall; a consultant and advisory board member for Almirall; a consultant for Bayer Healthcare; a consultant and speaker for Sensus Healthcare; a speaker and principal investigator for IFC, S.A.; a principal investigator and consultant for CROMA Pharma, Ferndale, and Johnson & Johnson; and a principal investigator for Actavis, Allergan, Annacor Pharmaceuticals, Biofrontera, Brickell Biotech, Cynova Laboratories, DUSA Pharmaceuticals, Demira, Evolus, Intraderm, LEO Pharma, MC2 Therapeutics, and SASIF & Sonoma. Dr. Weinkle is a consultant, principal investigator, advisory board member and speaker for Allergan; a stock holder and principal investigator for Derm Advance; an advisory board member, consultant, and speaker for Ethicon and Merz; a consultant and speaker for Galderma; a consultant for Procter & Gamble; and a principal investigator for Teoxane, Alphaeon, and Sinclair Pharma.

ACKNOWLEDGMENTS

The authors thank Ginny Vachon PhD of Principal Medvantage, LLC, Atlanta, Georgia, USA for providing medical writing support, provided by X-Medica, LLC with an educational grant from Sinclair.

REFERENCES

1. Farkas JP, Pessa JE, Hubbard B, Rohrich RJ. The science and theory behind facial aging. *Plast Reconstr Surg Glob Open*. 2013;1(1):e8-e15.
2. Cotofana S, Fratila AA, Schenck TL, Redka-Swoboda W, Zilinsky I, Pavicic T. The anatomy of the aging face: a review. *Facial Plast Surg*. 2016;32(3):253-260.
3. Kretlow JD, Hollier LH, Jr., Hatef DA. The facial aging debate of deflation versus attenuation: attenuation strikes back. *Plast Reconstr Surg*. 2012;130(1):180e-181e; author reply 182e.
4. Wong CH, Mendelson B. Newer understanding of specific anatomic targets in the aging face as applied to injectables: aging changes in the craniofacial skeleton and facial ligaments. *Plast Reconstr Surg*. 2015;136(5 Suppl):44S-48S.

© 2018-Journal of Drugs in Dermatology. All Rights Reserved.

This document contains proprietary information, images and marks of Journal of Drugs in Dermatology (JDD).

No reproduction or use of any portion of the contents of these materials may be made without the express written consent of JDD.

If you feel you have obtained this copy illegally, please contact JDD immediately at support@jddonline.com

5. Nestor MS, Ablon G, Andriessen A, et al. Expert consensus on absorbable advanced suspension technology for facial tissue repositioning and volume enhancement. *J Drugs Dermatol*. 2017;16(7):661-666.
6. Silhouette InstaLift™ [instructions for use]. Irvine, CA: Silhouette Lift Inc.; August 3, 2017.
7. Goldberg D, Guana A, Volk A, Daro-Kaftan E. Single-arm study for the characterization of human tissue response to injectable poly-L-lactic acid. *Dermatol Surg*. 2013;39(6):915-22.
8. Stein P, Vitavska O, Kind P, Hoppe W, Wiczorek H, Schurer NY. The biological basis for poly-L-lactic acid-induced augmentation. *J Dermatol Sci*. 2015;78(1):26-33.
9. Nestor MS. Facial lift and patient satisfaction following treatment: 12-month data - a prospective, masked, controlled clinical study. Poster presented at: 2018 South Beach Symposium (SBS); March 1-4, 2018; Miami Beach, FL. Abstract 66937.
10. Nestor MS. Improved patient satisfaction 12 months following treatment with Silhouette InstaLift™: data from a prospective, masked, controlled clinical study. Poster presented at: IMCAS World Congress 2018; February 1-3, 2018; Paris, France.
11. Jones D, Murphy DK. Volumizing hyaluronic acid filler for midface volume deficit: 2-year results from a pivotal single-blind randomized controlled study. *Dermatol Surg*. 2013;39(11):1602-1612.
12. Ogilvie MP, Few JW, Jr., Tomur SS, et al. Rejuvenating the face: an analysis of 100 absorbable suture suspension patients [published online December 8, 2017]. *Aesthet Surg J*.
13. Bauer U, Graivier MH. Optimizing injectable poly-L-lactic acid administration for soft tissue augmentation: the rationale for three treatment sessions. *Can J Plast Surg*. 2011;19(3):e22-e27.
14. Sinclair Pharma plc. Internal safety report. London, UK: December 2017.

AUTHOR CORRESPONDENCE

Z. Paul Lorenc MD FACS

E-mail: lorenc@lorenc.com