

ORIGINAL ARTICLE

Phase 3 Trials of Tirbanibulin Ointment for Actinic Keratosis

Andrew Blauvelt, M.D., Steven Kempers, M.D., Edward Lain, M.D., Todd Schlessinger, M.D., Stephen Tyring, M.D., Ph.D., Seth Forman, M.D., Glynis Ablon, M.D., George Martin, M.D., Hui Wang, Ph.D., David L. Cutler, M.D., Jane Fang, M.B., B.S., and Min-Fun R. Kwan, M.B., B.S., for the Phase 3 Tirbanibulin for Actinic Keratosis Group*

ABSTRACT

BACKGROUND

From the Oregon Medical Research Center, Portland (A.B.); the Minnesota Clinical Study Center, New Brighton (S.K.); the Austin Institute for Clinical Research, Pflugerville (E.L.), and the Department of Dermatology and Center for Clinical Studies, University of Texas Health Science Center at Houston, Houston (S.T.) — both in Texas; the Clinical Research Center of the Carolinas, Charleston, SC (T.S.); ForCare Clinical Research, Tampa, FL (S.F.); Ablon Skin Institute Research Center, Manhattan Beach, CA (G.A.); Dr. George Martin Dermatology Associates, Kihei, HI (G.M.); and Athenex, Buffalo, NY (H.W., D.L.C., J.F., M.-F.R.K.). Address reprint requests to Dr. Fang at Athenex, 1001 Main St., Suite 600, Buffalo, NY 14203, or at jfang@athenex.com.

The tubulin polymerization and Src kinase signaling inhibitor tirbanibulin is being investigated as a topical treatment for actinic keratosis, a precursor of squamous-cell carcinoma.

METHODS

In two identically designed double-blind trials, we randomly assigned, in a 1:1 ratio, adults with actinic keratoses on the face or scalp to receive either topical tirbanibulin or vehicle (placebo) ointment. The ointment was applied by the patients to a 25-cm² contiguous area containing four to eight lesions once daily for 5 consecutive days. The primary outcome was the percentage of patients with a complete (100%) reduction in the number of lesions in the application area at day 57. The secondary outcome was the percentage of patients with a partial (≥75%) reduction in the number of lesions within the application area at day 57. The incidence of recurrence was evaluated at 1 year. Local reactions were scored with the use of 4-point scale (ranging from 0 [absent] to 3 [severe]).

RESULTS

A total of 702 patients were enrolled in the two trials (351 patients per trial). Complete clearance in trial 1 occurred in 44% of the patients (77 of 175) in the tirbanibulin group and in 5% of those (8 of 176) in the vehicle group (difference, 40 percentage points; 95% confidence interval [CI], 32 to 47; P<0.001); in trial 2, the percentages were 54% (97 of 178 patients) and 13% (22 of 173), respectively (difference, 42 percentage points; 95% CI, 33 to 51; P<0.001). The percentages of patients with partial clearance were significantly higher in the tirbanibulin groups than in the vehicle groups. At 1 year, the estimated percentage of patients with recurrent lesions was 47% among patients who had had a complete response to tirbanibulin. The most common local reactions to tirbanibulin were erythema in 91% of the patients and flaking or scaling in 82%. Adverse events with tirbanibulin were application-site pain in 10% of the patients and pruritus in 9%, all of which resolved.

CONCLUSIONS

In two identically designed trials, tirbanibulin 1% ointment applied once daily for 5 days was superior to vehicle for the treatment of actinic keratosis at 2 months but was associated with transient local reactions and recurrence of lesions at 1 year. Trials comparing tirbanibulin with conventional treatments and that have longer follow-up are needed to determine the effects of tirbanibulin therapy on actinic keratosis. (Funded by Athenex; ClinicalTrials.gov numbers, NCT03285477 and NCT03285490.)

*A complete list of the investigators in the Phase 3 Tirbanibulin for Actinic Keratosis Group is provided in the Supplementary Appendix, available at NEJM.org.

N Engl J Med 2021;384:512-20.

DOI: 10.1056/NEJMoa2024040

Copyright © 2021 Massachusetts Medical Society.

ACTINIC KERATOSIS IS A COMMON PRE-cancerous condition found on sun-damaged skin, particularly on the face, scalp, arms, and legs.^{1,2} In the United States, the prevalence of actinic keratosis is approximately 58 million persons, with the condition commonly affecting men, persons with fair skin, persons with a history of prolonged exposure to ultraviolet light, and older persons.³⁻⁵ Left untreated, actinic keratosis may progress to invasive cutaneous squamous-cell carcinoma; the reported risk of progression ranges from 0.025 to 16% per lesion per year.^{6,7} Given the unpredictable nature of progression, treatment of all actinic keratoses has been recommended.⁸

Individual actinic keratosis lesions are typically treated with cryosurgery. Treatment of multiple lesions and surrounding solar-damaged skin (field therapy) includes topical agents (fluorouracil, diclofenac, imiquimod, or ingenol mebutate) and photodynamic therapy.¹ These treatments may be associated with local reactions of pain, irritation, erosions, ulcerations, and irreversible skin changes of pigmentation and scarring, and some treatments have to be administered over periods of weeks or months, which may reduce adherence and undermine treatment success.^{1,9-12}

Tirbanibulin 1% ointment is being investigated as a field therapy for actinic keratosis on the face or scalp. Tirbanibulin is a synthetic inhibitor of tubulin polymerization and Src kinase signaling.¹³ It induces p53 expression, arrest of cell division at interphase Gap 2 and mitosis in proliferating cell populations, and subsequent apoptosis by means of stimulation of caspase-3 and poly(adenosine diphosphate [ADP]-ribose) polymerase cleavage.¹³ In vitro, tirbanibulin has inhibited the growth of primary human keratinocytes¹³ and several melanoma cell lines. Phase 1 and 2 trials (ClinicalTrials.gov numbers, NCT02337205 and NCT02838628, respectively) showed that tirbanibulin ointment applied once daily for 3 or 5 days caused mild local irritation of the treated skin and cleared actinic keratoses on the dorsal forearm, face, and scalp.¹⁴ Here, we present the results of two identically designed phase 3 trials that evaluated the efficacy and safety of tirbanibulin ointment, as compared with vehicle ointment, applied for 5 days in adults with actinic keratoses on the face or scalp.

METHODS

TRIAL DESIGN AND OVERSIGHT

In these multicenter, double-blind, parallel-group, vehicle-controlled trials, eligible adult patients with four to eight clinically typical, visible, and discrete actinic keratosis lesions on the face or scalp within a contiguous area measuring 25 cm² were randomly assigned in a 1:1 ratio by means of a computer-generated random code to receive either tirbanibulin 1% ointment or vehicle ointment (placebo). Enrollment across patients was controlled to achieve a 2:1 ratio of facial:scalp treatment areas (i.e., to enroll twice as many patients with facial lesions as those with scalp lesions).

Key exclusion criteria were the presence of atypical, hypertrophic, recalcitrant, or rapidly changing actinic keratoses, open wounds or suspected skin cancers in proximity to the area where the ointment was to be applied, previous tirbanibulin treatment, and use of therapies on the application area within the previous 2 weeks. Sunscreen use was prohibited until day 57. The full inclusion and exclusion criteria are listed in the protocol, available with the full text of this article at NEJM.org. The protocol was identical for both trials.

Tirbanibulin 1% ointment and vehicle ointment, which contained monoglycerides, diglycerides, and propylene glycol, were supplied by the sponsor, Athenex, in identical single-dose packets. Ointment was applied by the patient to the entire 25-cm² area, once daily for 5 consecutive days. Safety and the number of lesions were assessed during the treatment period (days 1 to 5) and throughout the response-assessment period until day 57. The same investigator counted lesions at all visits for an individual patient. Patients who had 100% clearance of all lesions within the application area at day 57 continued in a 1-year follow-up to assess safety and response durability. A transparency sheet on which the lesions at baseline were mapped was used to identify new lesions (distinct from those at baseline) or recurrent lesions (same locations as at baseline) within the application area during the 1-year follow-up. Trial-group assignments remained masked to patients and assessors until completion of the 1-year follow-up.

The trials were conducted concurrently at 62 sites in the United States. The trials were con-

ducted in accordance with the principles of the Declaration of Helsinki, International Council for Harmonisation and Good Clinical Practice guidelines, and Title 21 of the U.S. Code of Federal Regulations regarding clinical trials. The conduct of the trial was overseen by Athenex. The trial protocols, informed-consent forms, and related documents were approved by a central institutional review board; all the patients provided written informed consent, including consent for the use of photographs of the application areas, before participation in the trial. The authors participated in the collection, analyses, and interpretation of the trial data. All the authors were involved in the preparation of the manuscript, and professional writing assistance was funded by the sponsor. All the authors vouch for the completeness and accuracy of the data, for the complete reporting of adverse events, and for the fidelity of the trials to the protocols. Confidentiality agreements were in place between the authors and the sponsor.

OUTCOMES

The primary efficacy outcome was the percentage of patients with complete (100%) clearance of all lesions within the application area at day 57. The primary efficacy population was the intention-to-treat population, which comprised all the patients who had undergone randomization. The secondary efficacy outcome was the percentage of patients with partial clearance, defined as a reduction of at least 75% in the number of lesions within the application area, at day 57. Patients with complete clearance of all lesions at day 57 were followed for 1 year to assess safety and the occurrence of lesions (new or recurrent) within the application area.

The safety population comprised all the patients who had undergone randomization and who received at least one dose of tirbanibulin or vehicle ointment. Safety assessments up to day 57 included the recording of local reaction scores, the evaluation of the absence or presence of pigmentation or scarring in the application area, adverse events, electrocardiographic monitoring or measurements, laboratory evaluations (hematologic and biochemical tests and urinalyses), physical examinations, and vital signs. During the 1-year follow-up, assessments of adverse events and serious adverse events continued.

Local reactions, defined as erythema, flaking

or scaling, crusting, swelling, vesiculation or pustulation, or erosions or ulceration,¹⁵ were recorded independently from adverse events. The application area was assessed by the investigators for each of six signs of local reactions with the use of a 4-point scale (with scores of 0 [absent], 1 [mild], 2 [moderate], and 3 [severe]).¹⁶ In addition, a composite score was calculated as the sum of the scores for all six signs (range, 0 to 18, with higher scores indicating more severe reactions) at each visit for each patient.

STATISTICAL ANALYSIS

On the basis of the chi-square method, we calculated that a planned sample of 300 patients per trial, with a trial-group assignment ratio of 1:1, would provide the trial with more than 90% power to detect a between-group difference of 20 percentage points for the primary outcome (assuming complete clearance in 30% of the patients in the tirbanibulin group and in 10% of those in the vehicle group) at a two-tailed significance level of 0.05. The primary outcome, the percentage of patients with complete (100%) clearance of all lesions within the application area at day 57, was analyzed by a Cochran–Mantel–Haenszel model controlling for application location (face or scalp) and trial group. Patients who discontinued the trial before day 57 or who missed the day 57 assessment were included in the analysis as having treatment failure. There was no imputation of missing data. The Pearson chi-square method (to power the trial) was applied to show basic agreement with the model for the primary outcome. The percentage of patients with partial ($\geq 75\%$) clearance was analyzed similarly.

To control for multiplicity, a step-down gate-keeping testing strategy was used for the overall type I error for the primary and secondary outcomes. The primary outcome was tested at the 0.05 significance level. If the result was significant, the secondary outcome of partial clearance would be tested at the same level.

Planned subgroup analyses were performed in subgroups that were defined according to application location (face or scalp), age (<65 years or ≥ 65 years), sex, number of lesions at baseline (4 to 6 vs. 7 or 8), and the Fitzpatrick skin type (I or II vs. III to VI) for the primary outcome with the use of the Clopper–Pearson method to estimate 95% confidence intervals. The scale for Fitzpatrick skin types ranges from I (always

burns, never tans) to VI (never burns). Other planned analyses included the mean and median reductions in the number of lesions from baseline (day 1) to day 57 and the Kaplan–Meier estimates of recurrence at 1 year among patients who had complete clearance at day 57. Safety was reported descriptively. The statistical analysis plan is available with the protocol at NEJM.org.

RESULTS

PATIENTS

The trials were conducted from September 2017 through April 2019. A total of 702 patients (351 in each trial) were enrolled, with approximately the same number of patients assigned to each group in each trial (Fig. 1). Two patients in the tirbanibulin groups, one in each trial, did not receive all five planned daily doses owing to a missed dose and an adverse event, in one patient each. Two patients in the vehicle group in trial 1 discontinued the trial before day 57 owing to suicide and relocation (withdrawal of consent), in one patient each, and were considered as not having had a response (owing to missing outcomes) at day 57. All the patients in trial 2 completed the trial through day 57.

The demographic and clinical characteristics of the patients at baseline were similar in the two groups in each trial. The majority of patients were White and male, with a Fitzpatrick skin type¹⁷ of I or II and a median of 6 lesions (interquartile range, 5 to 7) (Table 1). Across the groups in the two trials, 72 to 87% of the patients had previously been treated for actinic keratosis on the face or scalp (by cryosurgery in 63 to 75% of the patients and by previous field treatment in 31 to 38%), and 42 to 51% of the patients had a history of skin cancer.

EFFICACY

In trial 1, complete clearance of all lesions at day 57 (the primary outcome) occurred in 77 of 175 patients (44%) in the tirbanibulin group and in 8 of 176 patients (5%) in the vehicle group (difference, 40 percentage points; 95% confidence interval [CI], 32 to 47; $P < 0.001$); in trial 2, complete clearance occurred in 97 of 178 patients (54%) in the tirbanibulin group and in 22 of 173 patients (13%) in the vehicle group (difference, 42 percentage points; 95% CI, 33 to 51; $P < 0.001$) (Table 2). Across the two trials (pooled data),

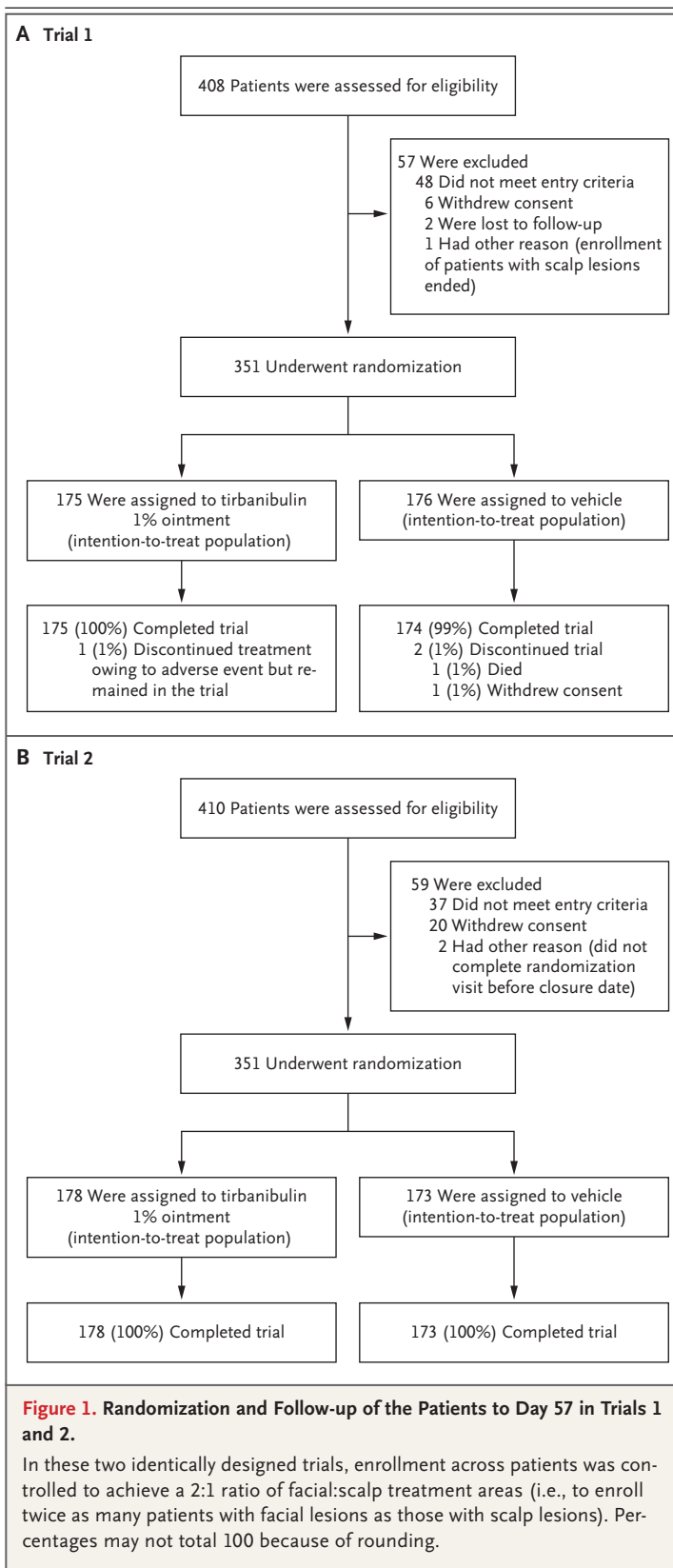


Table 1. Demographic and Clinical Characteristics of the Patients at Baseline (Intention-to-Treat Population).*

Characteristic	Trial 1		Trial 2	
	Tirbanibulin (N=175)	Vehicle (N=176)	Tirbanibulin (N=178)	Vehicle (N=173)
Age — yr	69.5±8.6	70.2±9.4	69.1±8.7	70.2±8.9
Male sex — no. (%)	147 (84)	154 (88)	158 (89)	150 (87)
White race — no. (%)†	175 (100)	175 (99)	177 (99)	173 (100)
Fitzpatrick skin type I or II — no. (%)‡	123 (70)	142 (81)	126 (71)	120 (69)
Median count of actinic keratosis lesions (IQR)	6 (5–7)	6 (5–7)	6 (5–7)	6 (5–7)
Face:scalp ratio of patients with the specified application location — no.§	119:56	121:55	119:59	118:55
History of treatment for actinic keratosis on face or scalp — no. (%)	145 (83)	153 (87)	132 (74)	125 (72)
History of skin cancer — no. (%)	77 (44)	89 (51)	75 (42)	72 (42)

* Plus-minus values are means ±SD. The intention-to-treat population comprised all the patients who had undergone randomization. IQR denotes interquartile range.

† Race was determined by the investigator.

‡ Fitzpatrick skin types range from I to VI: type I indicates always burns, never tans; type II, usually burns, tans minimally; type III, sometimes mildly burns, tans uniformly; type IV, burns minimally, always tans well; type V, very rarely burns, tans very easily; and type VI, never burns.

§ Enrollment across patients was controlled to achieve a 2:1 ratio of facial:scalp treatment areas (i.e., to enroll twice as many patients with facial lesions as those with scalp lesions).

Table 2. Complete and Partial Clearance of Actinic Keratosis Lesions on Day 57 in the Two Trials (Intention-to-Treat Population).*

Variable	Trial 1			Trial 2		
	Tirbanibulin (N=175)	Vehicle (N=176)	Difference (95% CI)	Tirbanibulin (N=178)	Vehicle (N=173)	Difference (95% CI)
	no./total no. (%)		percentage points	no./total no. (%)		percentage points
Complete clearance						
All locations	77/175 (44)	8/176 (5)	40 (32–47)	97/178 (54)	22/173 (13)	42 (33–51)
Face	60/119 (50)	7/121 (6)	45 (34–55)	73/119 (61)	16/118 (14)	48 (36–58)
Scalp	17/56 (30)	1/55 (2)	29 (16–42)	24/59 (41)	6/55 (11)	30 (12–45)
Partial clearance						
All locations	119/175 (68)	29/176 (16)	52 (43–60)	136/178 (76)	34/173 (20)	57 (48–65)
Face	90/119 (76)	23/121 (19)	57 (45–67)	95/119 (80)	26/118 (22)	58 (46–68)
Scalp	29/56 (52)	6/55 (11)	41 (23–56)	41/59 (69)	8/55 (15)	55 (37–69)

* Complete clearance was defined as a reduction of 100% in the number of lesions in the application area at day 57, and partial clearance as a reduction of at least 75%. For the differences in the analyses of all locations, the differences, confidence intervals, and P values were estimated with the use of a Cochran–Mantel–Haenszel method with adjustment for application location ($P < 0.001$ for all comparisons). For the subgroup analyses (face or scalp), confidence intervals were estimated on the basis of a binomial Clopper–Pearson method and were not adjusted for multiple comparisons.

complete clearance occurred in 174 of 353 patients (49%) in the tirbanibulin groups and in 30 of 349 patients (9%) in the vehicle groups (difference, 41 percentage points; 95% CI, 35 to 47).

In trial 1, partial clearance ($\geq 75\%$ reduction in the number of lesions) at day 57 (the secondary outcome) occurred in 119 of 175 patients (68%) in the tirbanibulin group and in 29 of 176 patients (16%) in the vehicle group (difference,

52 percentage points; 95% CI, 43 to 60; $P < 0.001$); in trial 2, partial clearance occurred in 136 of 178 patients (76%) in the tirbanibulin group and in 34 of 173 patients (20%) in the vehicle group (difference, 57 percentage points; 95% CI, 48 to 65; $P < 0.001$) (Table 2). Across the two trials (pooled data), partial clearance occurred in 255 of 353 patients (72%) in the tirbanibulin groups and in 63 of 349 (18%) in the vehicle

groups (difference, 54 percentage points; 95% CI, 48 to 60).

The incidence of complete clearance with tirbanibulin was compared with the incidence with vehicle in prespecified subgroups in the two trials (Table S1 in the Supplementary Appendix, available at NEJM.org). Confidence intervals for the subgroup analyses were not adjusted for multiple comparisons, and no clinical conclusions can be drawn from these data.

Reductions in the number of lesions within the application area over time up to day 57 are shown in Figure S1. At day 57, the mean percent reduction in the number of lesions, as compared with baseline, was 76% in the tirbanibulin group and 28% in the vehicle group in trial 1 and 82% and 34%, respectively, in trial 2. The median percent reduction in the number of lesions, as compared with baseline, was 83% in the tirbanibulin group and 20% in the vehicle group in trial 1 and 100% and 25%, respectively, in trial 2.

FOLLOW-UP AT 1 YEAR

Of the 174 patients who received tirbanibulin (77 patients in trial 1 and 97 in trial 2) who had complete clearance, 124 had one or more lesions develop within the application area during follow-up. Of these 124 patients, 72 (58%) had recurrent lesions (reappearance during follow-up) and 52 (42%) had new lesions only (distinct from baseline). At 1 year, the Kaplan–Meier estimate of the percentage of patients with recurrent lesions was 47% and the estimate of the percentage of those with recurrent or new lesions within the application area was 73%; the estimate of sustained complete clearance was 27%.

SAFETY

At baseline, before the trial regimen was begun, approximately one third of the patients had mild erythema, flaking or scaling, and crusting. After the initiation of the trial regimen, the mean local-reaction composite scores in patients who received tirbanibulin increased by day 8 to a maximum of 4.0 in trial 1 and 4.3 in trial 2. These values were approximately half the maximum value observed at day 15 and were at or below the baseline value by day 29 (0.6 in trial 1 and 0.6 in trial 2) (Fig. S2). The most common local reactions were erythema (in 91% of the patients) and flaking or scaling (in 82%). When the maximal local reactions above baseline were considered, moderate erythema was more frequently observed with

tirbanibulin than with vehicle ointment (Table 3). Crusting, swelling, vesiculation or pustulation, and erosion or ulceration occurred less frequently than erythema and flaking or scaling and were generally mild. Severe local reactions were infrequent among tirbanibulin-treated patients in the two trials (Table 3).

Local reactions resolved spontaneously. Photographs of local reactions in selected patients are shown in Figure S3. Among patients who received tirbanibulin, the incidence of hypopigmentation, hyperpigmentation, and scarring was 14%, 16%, and 7%, respectively, at baseline and was 12%, 10%, and 5%, respectively, at day 57.

The incidence and severity of adverse events were similar in the tirbanibulin groups and the vehicle groups in both trials. No serious adverse events or discontinuations related to tirbanibulin or vehicle ointment occurred. In trial 1, adverse events occurred in 33% of the patients who received tirbanibulin and in 32% of those who received vehicle ointment; in trial 2, adverse events occurred in 38% and 39% of the patients, respectively (Table 4). Most adverse events were mild. The most common adverse events were application-site pruritus and application-site pain (Table 4), which resolved without intervention. One patient had severe application-site pruritus, which resolved spontaneously. Other common adverse events (occurring in >2% of the patients) were upper respiratory tract infection, viral upper respiratory tract infection, and skin abrasion, with no substantial differences between the trial groups in each trial. There were no clinically significant changes in electrocardiograms, laboratory findings, physical examinations, or vital signs.

Across the two trials, squamous-cell cancer developed in 10 patients outside the application area. One tirbanibulin-treated patient, who did not have complete clearance of lesions, had new-onset squamous-cell cancer within the application area. During the 1-year follow-up, adverse events occurred in no more than 5% of the patients in each trial.

DISCUSSION

Tirbanibulin is a synthetic, antiproliferative agent that binds tubulin, inhibits tubulin polymerization, and disrupts Src signaling in actively dividing cells.¹³ In two phase 3 trials, tirbanibulin 1% ointment, applied by the patient once daily for 5 days, resulted in higher percentages of patients

Table 3. Maximal Local Skin Reactions Greater than Those at Baseline within the Application Area in the Two Trials (Safety Population).*

Skin Reaction on Face or Scalp	Tirbanibulin			Vehicle		
	Mild	Moderate	Severe	Mild	Moderate	Severe
	<i>number of patients/total number (percent)</i>					
Trial 1						
Erythema	41/175 (23)	116/175 (66)	5/175 (3)	57/176 (32)	8/176 (5)	0/176
Flaking or scaling	49/175 (28)	78/175 (45)	11/175 (6)	46/176 (26)	14/176 (8)	0/176
Crusting	62/175 (35)	20/175 (11)	2/175 (1)	23/176 (13)	2/176 (1)	0/176
Swelling	55/175 (31)	12/175 (7)	1/175 (1)	12/176 (7)	1/176 (1)	0/176
Vesiculation or pustulation	14/175 (8)	2/175 (1)	1/175 (1)	2/176 (1)	0/176	0/176
Erosion or ulceration	14/175 (8)	5/175 (3)	0/175	8/176 (5)	0/176	0/176
Trial 2						
Erythema	35/178 (20)	107/178 (60)	17/178 (10)	41/173 (24)	12/173 (7)	0/173
Flaking or scaling	43/178 (24)	88/178 (49)	20/178 (11)	40/173 (23)	19/173 (11)	1/173 (1)
Crusting	45/178 (25)	30/178 (17)	5/178 (3)	8/173 (5)	6/173 (3)	0/173
Swelling	47/178 (26)	20/178 (11)	1/178 (1)	3/173 (2)	0/173	0/173
Vesiculation or pustulation	11/178 (6)	0/178	1/178 (1)	1/173 (1)	0/173	0/173
Erosion or ulceration	18/178 (10)	4/178 (2)	0/178	2/173 (1)	0/173	0/173
Pooled trials						
Erythema	76/353 (22)	223/353 (63)	22/353 (6)	98/349 (28)	20/349 (6)	0/349
Flaking or scaling	92/353 (26)	166/353 (47)	31/353 (9)	86/349 (25)	33/349 (9)	1/349 (<1)
Crusting	107/353 (30)	50/353 (14)	7/353 (2)	31/349 (9)	8/349 (2)	0/349
Swelling	102/353 (29)	32/353 (9)	2/353 (1)	15/349 (4)	1/349 (<1)	0/349
Vesiculation or pustulation	25/353 (7)	2/353 (1)	2/353 (1)	3/349 (1)	0/349	0/349
Erosion or ulceration	32/353 (9)	9/353 (3)	0/353	10/349 (3)	0/349	0/349

* The safety population comprised all the patients who had undergone randomization and who received at least one dose of tirbanibulin or vehicle ointment. Local skin reactions were graded on a 4-point scale, with a score of 0 indicating absent, 1 mild (slightly or barely perceptible), 2 moderate (distinct presence), and 3 severe (marked or intense).

with complete and partial clearance of actinic keratosis lesions than vehicle at day 57. The active treatment was associated with an estimated 47% of the patients with complete clearance having recurrent lesions at the 1-year follow-up.

Local reactions were mostly mild-to-moderate erythema, flaking or scaling, application-site pruritus, and application-site pain that resolved spontaneously. Unlike with most topical treatments for actinic keratosis,^{1,9-12} severe local reactions, including vesiculation or pustulation and erosion or ulceration, were infrequent with tirbanibulin ointment. This could be due to the relatively short, 5-day course of once-daily treatment. Systemic adverse events were uncommon, a finding that is consistent with the negligible systemic absorption of tirbanibulin.¹⁸

No comparisons can be made between tirban-

ibulin and other treatments because of differences in trial design and in the populations included in the trials. Commonly prescribed topical treatments for actinic keratosis on the face and scalp include fluorouracil, diclofenac, imiquimod, and ingenol mebutate, which have treatment durations ranging from 3 days to 4 months, with reported complete clearance in 31 to 48% of patients, as compared with 3 to 17% of patients who received vehicle ointment.¹⁹⁻²⁶ Tirbanibulin ointment, when applied by the patient once daily for 5 days, led to complete lesion clearance in 44% of the patients in trial 1 and 54% in trial 2, as compared with 5% and 13% of the patients, respectively, who had been assigned to receive vehicle ointment. The median reduction in the number of lesions that was observed with tirbanibulin was consistent with those reported for ingenol mebutate.²¹

Table 4. Adverse Events to Day 57 in the Two Trials, Separately and Pooled (Safety Population).*

Event	Trial 1		Trial 2		Pooled Trials	
	Tirbanibulin (N=175)	Vehicle (N=176)	Tirbanibulin (N=178)	Vehicle (N=173)	Tirbanibulin (N=353)	Vehicle (N=349)
	<i>number (percent)</i>					
Any serious adverse event†	0	2 (1)	1 (1)	4 (2)	1 (<1)	6 (2)
Any severe adverse event	2 (1)	2 (1)	1 (1)	4 (2)	3 (1)	6 (2)
Any adverse event	57 (33)	57 (32)	67 (38)	67 (39)	124 (35)	124 (36)
Application-site pain‡	11 (6)	6 (3)	24 (13)	5 (3)	35 (10)	11 (3)
Application-site pruritus	13 (7)	8 (5)	19 (11)	13 (8)	32 (9)	21 (6)
Upper respiratory tract infection	6 (3)	7 (4)	7 (4)	10 (6)	13 (4)	17 (5)
Viral upper respiratory tract infection	3 (2)	5 (3)	8 (4)	4 (2)	11 (3)	9 (3)
Skin abrasion	4 (2)	5 (3)	3 (2)	3 (2)	7 (2)	8 (2)

* Adverse events with an incidence of more than 2% in any trial group are reported here. Some patients had more than one adverse event. The adverse events are listed according to the order of frequency in the tirbanibulin group in the pooled trials.

† No serious adverse event was considered by the investigators to be related to tirbanibulin or vehicle ointment. In the vehicle group in trial 1, one patient died from suicide, and one had myocardial infarction and aortic-valve stenosis. In trial 2, one patient in the tirbanibulin group had pulmonary embolism and chest pain; in the vehicle group, one patient had hip pain and intervertebral disk degeneration, one had complete heart block, one had chest pain, and one had bacteremia.

‡ Application-site pain included pain, tenderness, stinging, and burning sensation at the application site.

Owing to the chronic nature of actinic keratosis, the recurrence and development of new lesions in sun-damaged skin are expected.^{27,28} The incidence of recurrence with conventional treatment^{29,30} has ranged from 20 to 96%.^{22,31,32} Among patients who had complete clearance at day 57 in the current trials, the estimated incidence of recurrence of previously cleared lesions was 47% at 1 year; the estimated incidence of any lesions (new or recurrent) within the application area was 73%.

As in other trials of treatment for actinic keratosis, 42 to 51% of the patients in these trials had a history of skin cancer.²¹ Throughout the limited duration of the current trials, squamous-cell cancer developed in less than 2% of the patients, all of whom had a history of skin cancer. All the skin cancers were outside the application area except in one tirbanibulin-treated patient who had a new squamous-cell cancer inside the application area.

A limitation in these two trials was that the investigators could have been aware of the trial-group assignments because of the presence of local reactions. Another limitation was the restriction of the application area to a small area on the face or scalp.

In these two trials, tirbanibulin 1% ointment applied once daily for 5 days was superior to vehicle ointment as topical treatment for actinic

keratosis on the face and scalp at 2 months but was associated with transient local reactions and a recurrence of lesions at 1 year. Larger and longer trials are necessary to determine the effects and risks of tirbanibulin therapy among patients with actinic keratosis.

Supported by Athenex.

Dr. Blauvelt reports receiving consulting fees and lecture fees from AbbVie and consulting fees from Almirall, Arena Pharmaceuticals, Athenex, Boehringer Ingelheim, Bristol Myers Squibb, Dermavant Sciences, Eli Lilly, Forte Biosciences, Galderma Laboratories, Incyte, Janssen Biotech, LEO Pharma, Novartis, Pfizer, Rapt Therapeutics, Regeneron Pharmaceuticals, Sanofi Genzyme, Sun Pharmaceutical Industries, and UCB Pharma; Dr. Kempers, receiving consulting fees from Athenex; Dr. Lain, receiving advisory board fees, consulting fees, and fees for serving on a speakers' bureau from Almirall, consulting fees from Athenex, and consulting fees and advisory board fees from LEO Pharma; Dr. Schlesinger, receiving grant support, paid to the Clinical Research Center of the Carolinas, and consulting fees from Almirall, grant support, paid to the Clinical Research Center of the Carolinas, from Galderma Research and Development and Kinex Medical, and consulting fees and lecture fees from Sun Pharmaceutical Industries; Dr. Tyring, receiving grant support, paid to the Center for Clinical Studies, from Athenex; Dr. Forman, receiving consulting fees from Eli Lilly, Incyte, and Pfizer; Dr. Martin, receiving consulting fees from Almirall, Athenex, LEO Pharma, and Ortho Dermatologics and advisory board fees from Biofrontera and Sun Pharmaceutical Industries; Dr. Wang, being employed by and owning stock and stock options in Athenex; Dr. Cutler, being employed by and owning stock in Athenex; Dr. Fang, receiving consulting fees from and owning stock and stock options in Athenex; and Dr. Kwan, being employed by and owning stock and stock options in Athenex and owning stock in Merck. No other potential conflict of interest relevant to this article was reported.

Disclosure forms provided by the authors are available with the full text of this article at NEJM.org.

A data sharing statement provided by the authors is available with the full text of this article at NEJM.org.

We thank the preclinical and clinical teams at Athenex for assistance; Dr. Harold Amkraut for contributions to the trial design and for statistical guidance; Dr. Edwin Peets for contributions to the clinical program; Dr. Johnson Lau for his inception

and guidance of the actinic keratosis program; and Dr. Lorraine Basso, of Basso Consulting, and Drs. Gemma McGregor and Claire Lavin, of McCann Health Medical Communications, for medical writing assistance with an earlier version of the manuscript, funded by Athenex and Almirall, in accordance with Good Publication Practice guidelines.

REFERENCES

1. Khanna R, Bakshi A, Amir Y, Goldenberg G. Patient satisfaction and reported outcomes on the management of actinic keratosis. *Clin Cosmet Investig Dermatol* 2017;10:179-84.
2. Richard MA, Amici JM, Basset-Seguin N, Claudel JP, Cribier B, Dreno B. Management of actinic keratosis at specific body sites in patients at high risk of carcinoma lesions: expert consensus from the AKTeam™ of expert clinicians. *J Eur Acad Dermatol Venereol* 2018;32:339-46.
3. The Lewin Group. The burden of skin diseases. 2005 (http://www.lewin.com/content/dam/Lewin/Resources/Site_Sections/Publications/april2005skindisease.pdf).
4. Memon AA, Tomenson JA, Bothwell J, Friedmann PS. Prevalence of solar damage and actinic keratosis in a Merseyside population. *Br J Dermatol* 2000;142:1154-9.
5. Balcer A, Rone Kupfere M, Čema I, Krūmiņa A. Prevalence, discontinuation rate, and risk factors for severe local site reactions with topical field treatment options for actinic keratosis of the face and scalp. *Medicina (Kaunas)* 2019;55:92.
6. Marks R, Rennie G, Selwood TS. Malignant transformation of solar keratoses to squamous cell carcinoma. *Lancet* 1988; 1:795-7.
7. Glogau RG. The risk of progression to invasive disease. *J Am Acad Dermatol* 2000;42:23-4.
8. Reynolds KA, Schlessinger DJ, Vasic J, et al. Core outcome set for actinic keratosis clinical trials. *JAMA Dermatol* 2020; 156:326-33.
9. Ibrahim SF, Brown MD. Actinic keratoses: a comprehensive update. *J Clin Aesthet Dermatol* 2009;2:43-8.
10. American Academy of Dermatology. Actinic keratosis. 2019 (<https://www.aad.org/public/diseases/scaly-skin/actinic-keratosis#overview>).
11. Goldenberg G. Treatment considerations in actinic keratosis. *J Eur Acad Dermatol Venereol* 2017;31:Suppl 2:12-6.
12. Del Rosso JQ, Kircik L, Goldenberg G, Brian B. Comprehensive management of actinic keratoses: practical integration of available therapies with a review of a newer treatment approach. *J Clin Aesthet Dermatol* 2014;7:9 Suppl:S2-S12.
13. Smolinski MP, Bu Y, Clements J, et al. Discovery of novel dual mechanism of action Src signaling and tubulin polymerization inhibitors (KX2-391 and KX2-361). *J Med Chem* 2018;61:4704-19.
14. Kempers S, DuBois J, Forman S, et al. Tirbanibulin ointment 1% as a novel treatment for actinic keratosis: phase 1 and 2 results. *J Drugs Dermatol* 2020;19: 1093-100.
15. Rosen R, Marmur E, Anderson L, Welburn P, Katsamas J. A new, objective, quantitative scale for measuring local skin responses following topical actinic keratosis therapy with ingenol mebutate. *Dermatol Ther (Heidelb)* 2014;4:207-19.
16. Food and Drug Administration. Draft guidance on ingenol mebutate. January 2016 (https://www.accessdata.fda.gov/drugsatfda_docs/psg/Ingenol%20Mebutate%20Topical%20Gel%200.015_NDA%20202833%20RV%20Feb%202019.pdf).
17. Fitzpatrick TB. The validity and practicality of sun-reactive skin types I through VI. *Arch Dermatol* 1988;124:869-71.
18. Yavel R, Overcash JS, Zhi J, Cutler D, Fang J. Phase I maximal use pharmacokinetic study of tirbanibulin ointment 1% in subjects with actinic keratosis. Presented at the annual meeting of the European Association of DermatoOncology, Vilnius, Lithuania, October 12–14, 2020.
19. 3M Health Care. Aldara (imiquimod) prescribing information. 2010. (Accessed July 2020, at https://www.accessdata.fda.gov/drugsatfda_docs/label/2010/020723s022lbl.pdf).
20. Almirall. Solaraze (diclofenac sodium) prescribing information. 2019 (<https://www.medicines.org.uk/emc/product/6385/smpe>).
21. Lebwohl M, Swanson N, Anderson LL, Melgaard A, Xu Z, Berman B. Ingenol mebutate gel for actinic keratosis. *N Engl J Med* 2012;366:1010-9.
22. Pomerantz H, Hogan D, Eilers D, et al. Long-term efficacy of topical fluorouracil cream, 5%, for treating actinic keratosis: a randomized clinical trial. *JAMA Dermatol* 2015;151:952-60.
23. Rivers JK, Arlette J, Shear N, Guenther L, Carey W, Poulin Y. Topical treatment of actinic keratoses with 3.0% diclofenac in 2.5% hyaluronan gel. *Br J Dermatol* 2002; 146:94-100.
24. Swanson N, Abramovits W, Berman B, Kulp J, Rigel DS, Levy S. Imiquimod 2.5% and 3.75% for the treatment of actinic keratoses: results of two placebo-controlled studies of daily application to the face and balding scalp for two 2-week cycles. *J Am Acad Dermatol* 2010;62:582-90.
25. Valeant Pharmaceuticals North America. Efidex (fluorouracil) prescribing information. 2019 (<https://www.drugs.com/pro/efudex.html>).
26. Weiss J, Menter A, Hevia O, et al. Effective treatment of actinic keratosis with 0.5% fluorouracil cream for 1, 2, or 4 weeks. *Cutis* 2002;70:Suppl:22-9.
27. Skov T, Stockfleth E, Szeimies RM, Berman B. Efficacy endpoints in clinical trials in actinic keratosis. *Dermatol Ther (Heidelb)* 2018;8:425-33.
28. Werner RN, Sammain A, Erdmann R, Hartmann V, Stockfleth E, Nast A. The natural history of actinic keratosis: a systematic review. *Br J Dermatol* 2013;169: 502-18.
29. Cramer P, Stockfleth E. Actinic keratosis: where do we stand and where is the future going to take us? *Expert Opin Emerg Drugs* 2020;25:49-58.
30. Gollnick H, Dirschka T, Ostendorf R, Kerl H, Kunstfeld R. Long-term clinical outcomes of imiquimod 5% cream vs. diclofenac 3% gel for actinic keratosis on the face or scalp: a pooled analysis of two randomized controlled trials. *J Eur Acad Dermatol Venereol* 2020;34:82-9.
31. Dirschka T, Ekanayake-Bohlig S, Dominicus R, et al. A randomized, intraindividual, non-inferiority, phase III study comparing daylight photodynamic therapy with BF-200 ALA gel and MAL cream for the treatment of actinic keratosis. *J Eur Acad Dermatol Venereol* 2019;33:288-97.
32. Krawtchenko N, Roewert-Huber J, Ulrich M, Mann I, Sterry W, Stockfleth E. A randomised study of topical 5% imiquimod vs. topical 5-fluorouracil vs. cryosurgery in immunocompetent patients with actinic keratoses: a comparison of clinical and histological outcomes including 1-year follow-up. *Br J Dermatol* 2007;157: Suppl 2:34-40.

Copyright © 2021 Massachusetts Medical Society.